



SRI RAMAKRISHNA DENTAL COLLEGE & HOSPITAL

(Educational Service : SNR Sons Charitable Trust)

Affiliated to the Tamilnadu Dr. M.G.R. Medical University, Chennai,
Recognised by Dental Council of India, New Delhi



E-POSTER

DEPARTMENT OF CONSERVATIVE DENTISTRY AND ENDODONTICS

FISH CONCEPT - AISHWARYA NAIR, ANBUMUKHIL, ANNALAKSHMI.A

ZONE OF INFECTION

- CONFINED TO THE CENTER OF THE LESION
- MIDUS OF INFECTION
- MICROORGANISMS FOUND ONLY IN THIS AREA

ZONE OF CONTAMINATION

- ZONE OF CELLULAR DESTRUCTION
- HIGH LEVEL OF TOXINS
- LACUNAE APPEAR EMPTY DUE TO AUTOLYSIS OF BONE CELLS

FISH CONCEPT

IN 1959, FISH STUDIED THE REACTION OF PERIRADICULAR TISSUES TO NOXIOUS PRODUCTS OF TISSUE NECROSIS, BACTERIAL PRODUCTS AND ANTIGENIC AGENTS FROM THE ROOT CANAL USING GUINEA PIGS.

HE DESCRIBED FOUR ZONES:

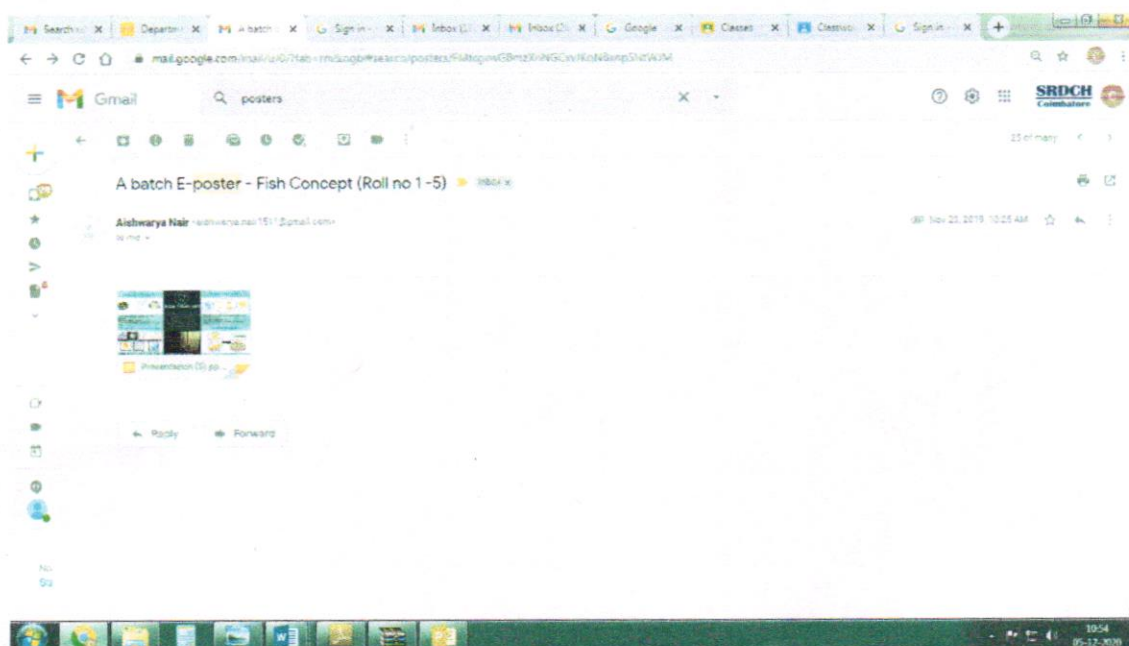
1. ZONE OF INFECTION
2. ZONE OF CONTAMINATION
3. ZONE OF IRRITATION
4. ZONE OF STIMULATION

ZONE OF IRRITATION

- MACROPHAGES AND OSTEOCLASTS ARE SEEN
- DILUTED TOXINS
- COLLAGEN DEGRADATION
- EVIDENCE OF BODY'S ATTEMPT TO INITIATE REPAIR

ZONE OF STIMULATION

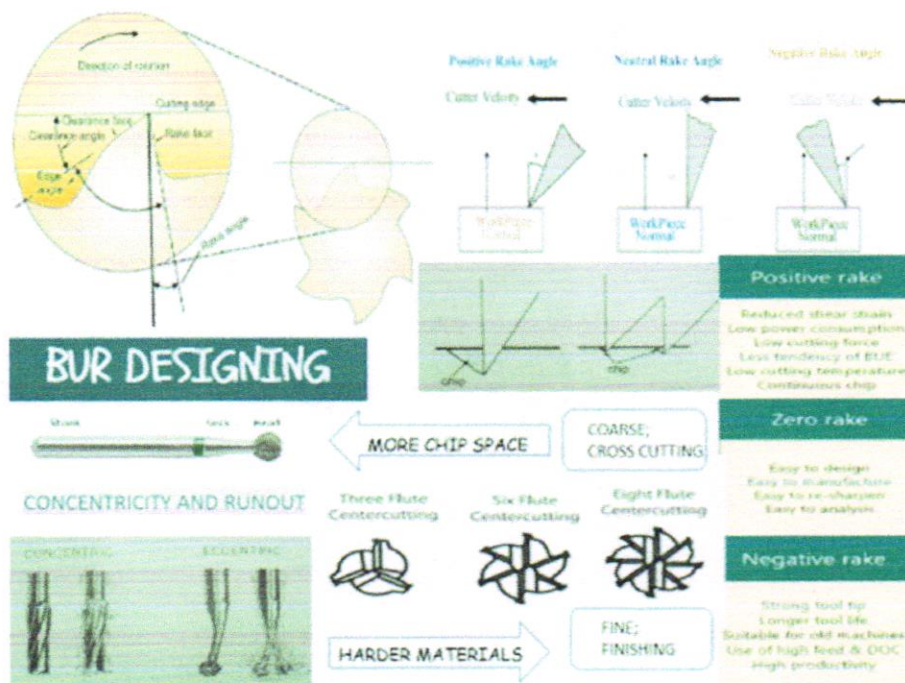
- SEVERLY DILUTED BACTERIAL TOXINS
- FIBROBLASTS AND OSTEOBLASTS SEEN
- IRREGULAR BONE MATRIX IS FORMED



Principal
 Sri Ramakrishna Dental College & Hospital
 S.N.R. College Road, COIMBATORE - 641 006.

ETCHING OF DENTAL SURFACE WITH ACID TO REMOVE THE SMEAR LAYER AND OPEN THE DENTINAL TUBULES, INCREASES RETENTION OF RESIN SEALANTS AND PROMOTE MECHANICAL RETENTION.

BUR DESIGN – BAVANANDHINI



BUR DESIGN:

THE BUR HEAD MAY BE DIVIDED INTO SIX OR EIGHT BLADES

ALSO CALLED TEETH OR FLUTES


EACH FLUTE OR BLADE HAS A LEADING SIDE - RAKE FACE AND TRAILING SIDE - CLEARANCE FACE

THREE ANGLE :

- RAKE ANGLE
- EDGE ANGLE
- CLEARANCE ANGLE


Handwritten signature

Principal
Sri Ramakrishna Dental College & Hospital
S.N.R. College Road, COIMBATORE - 641 006.



ORAL CANCER AWARENESS

-PREVENTION IS BETTER THAN CURE



WHAT IS ORAL CANCER? Includes cancer of lips, tongue, cheeks, floor of mouth, hard and soft palate, sinuses and pharynx

Cause/Risk factors

- Tobacco
- Alcohol
- Betel quid and areca nut
- Human papillomavirus (HPV)
- Previous cancer
- Family history of squamous cell carcinoma (skin cancer)
- Inherited conditions

HOW TO CURE?

- 1.Surgery
- 2.radiation therapy
- 3.targeted therapy
- 4.nutritious food
5. Keeping mouth healthy

DOES IT SPREAD? Cancer cells have the potential to spread from oral cavity to other organs (METASTASIS)

STAYING HEALTHY

- 1. Brush your teeth
- 2. Floss
- 3. Visit your dentist
- 4. Avoid tobacco
- 5. Limit alcohol

COMMON SYMPTOMS:

- 1. A lump or thickening in the cheek
- 2. A sore that does not heal
- 3. Persistent hoarseness
- 4. Difficulty swallowing
- 5. Unexplained weight loss

How to prevent?

Practicing good oral hygiene is a good start

Self examine your mouth for ulceration, patch

Keeping your mouth and throat healthy

Steer clear of tobacco

Drink alcohol in moderation

See your dentist regularly

Get vaccinated for HPV (human papillomavirus)

Shield your lips from the sun

DID YOU KNOW?

Fun Dental Facts

FACTS

1. Oral cancer is fairly common. It tops in top three cancers in India
2. Survival is not more than five years
3. One person dies of oral cancer every single hour of the day
4. Oral cancer is twice as likely in men than in women

Cost of treatment is about 3.5 lakhs

ORAL CANCER

▪GROUP OF NEOPLASM AFFECTING ANY REGION OF ORAL CAVITY, PHARYNGEAL REGION AND SALIVARY GLAND

ORAL SQUAMOUS CELL CARCINOMA

Squamous - flat cells lining surface


Carcinoma- cancer in epithelial cells.

CAUSES:

Tobacco, alcohol, non ionizing radiations, virus and genetic factors

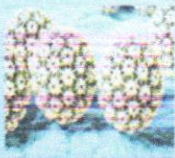
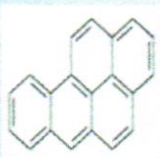
SYMPTOMS:

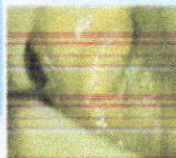

Premalignant lesions, erythroplakia, leucoplakia, submucous fibrosis




PREVENTION:

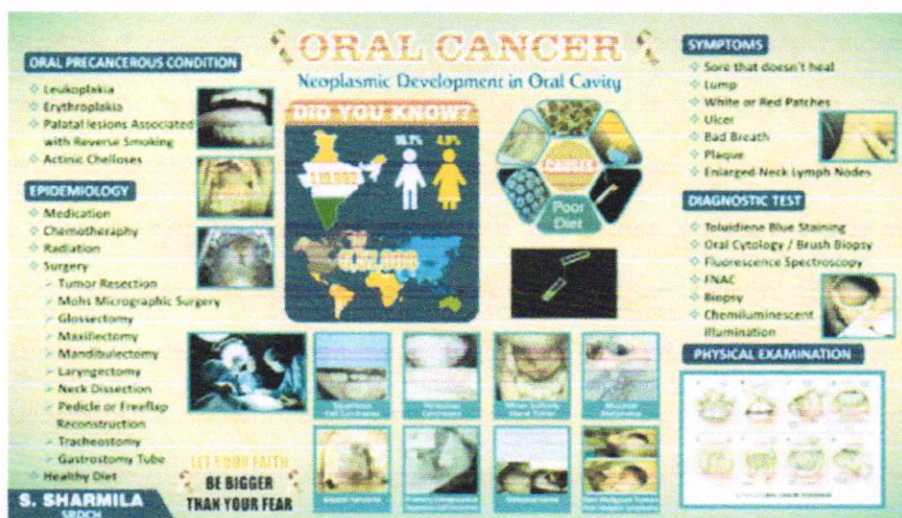Premalignancy screening, Chemoprevention, immunotherapy, awareness.



Principal
 Sri Ramakrishna Dental College & Hospital
 S.N.R. College Road, COIMBATORE - 641 006.



DEPARTMENT OF ORAL PATHOLOGY AND MICROBIOLOGY

ORAL CANCER AWARENESS SURVEY

DEAR SIR/MADAM

YOU ARE INVITED TO PARTICIPATE IN A RESEARCH STUDY TITLED "ORAL CANCER AWARENESS". THIS STUDY IS BEING CONDUCTED BY DEPARTMENT OF ORAL PATHOLOGY AND MICROBIOLOGY, SRI RAMAKRISHNA DENTAL COLLEGE AND HOSPITAL, COIMBATORE. IN THIS STUDY, YOU WILL BE ASKED TO COMPLETE A WRITTEN SURVEY. YOUR PARTICIPATION IN THIS STUDY IS VOLUNTARY AND YOU ARE FREE TO WITHDRAW YOUR PARTICIPATION FROM THIS STUDY AT ANY TIME. INFORMATION COLLECTED IN THIS STUDY MAY HELP US IN BETTER UNDERSTANDING THE AWARENESS OF THE PUBLIC TOWARDS ORAL CANCER.

BY COMPLETING AND SUBMITTING THIS SURVEY, YOU ARE INDICATING YOUR CONSENT TO PARTICIPATE IN THE STUDY. YOUR PARTICIPATION IS APPRECIATED.

INVESTIGATOR'S SIGNATURE
SIGNATURE

PARTICIPANT'S

AGE OF THE PARTICIPANT:

SEX :

QUALIFICATION :

OCCUPATION :

HABITS IF ANY : SMOKING/ALCOHOL/TOBACCO CHEWING

Principal
Sri Ramakrishna Dental College & Hospital
S.N.R. College Road, COIMBATORE - 641 006.

QUESTIONNAIRE

1. ARE YOU AWARE OF THE TERM "ORAL CANCER"?

a) YES B) NO C) NOT SURE

2. DO YOU THINK THAT PEOPLE OVER 45 YEARS ARE AT INCREASED RISK OF GETTING ORAL CANCER?

a) YES B) NO C) NOT SURE

3. DO YOU THINK ORAL CANCER OCCUR ONLY IN MALES?

a) YES B) NO C) NOT SURE

4. DO YOU THINK ORAL CANCER MANIFEST WITHOUT PAIN OR INITIAL SYMPTOMS?

a) YES B) NO C) NOT SURE

5. DO YOU KNOW THAT EARLY DETECTION OF ORAL CANCER CAN PREVENT LIFE THREATENING/GRAVE ILLNESS CONDITIONS?

A) YES B) NO C) NOT SURE

6. IS ORAL CANCER A CONTAGIOUS DISEASE?

A) YES B) NO C) NOT SURE

7. DO YOU THINK THAT USAGE OF TOBACCO IN ANY FORM WILL INCREASE A PERSON'S CHANCE OF GETTING ORAL CANCER?

A) YES B) NO C) NOT SURE

8. DO YOU THINK THAT REGULAR ALCOHOL DRINKING WILL INCREASE A PERSON'S CHANCE OF GETTING ORAL CANCER?

A) YES B) NO C) NOT SURE

9. DO YOU THINK EXCESSIVE SUNRAY EXPOSURE WILL INCREASE A PERSON'S CHANCE OF GETTING ORAL CANCER?

A) YES B) NO C) NOT SURE

10. DO YOU THINK LACK OF FRUITS AND VEGETABLES WILL INCREASE A PERSON'S CHANCE OF GETTING ORAL CANCER?

A) YES B) NO C) NOT SURE

11. DO YOU THINK THAT FREQUENT CHEEK BITING WILL INCREASE A PERSON'S CHANCE OF GETTING ORAL CANCER?

A) YES B) NO C) NOT SURE



Principal

Sri Ramakrishna Dental College & Hospital
S.N.R. College Road, COIMBATORE - 541 006.

12. ARE YOU AWARE OF OCCURRENCE OF ORAL CANCER WITHOUT THE HABITS MENTIONED ABOVE?

A)YES B)NO C) NOT SURE

13. DO YOU KNOW THAT HPV VACCINE FOR BOTH MEN AND WOMEN THAT CAN PREVENT CANCER?

A) YES B)NO C)NOT SURE

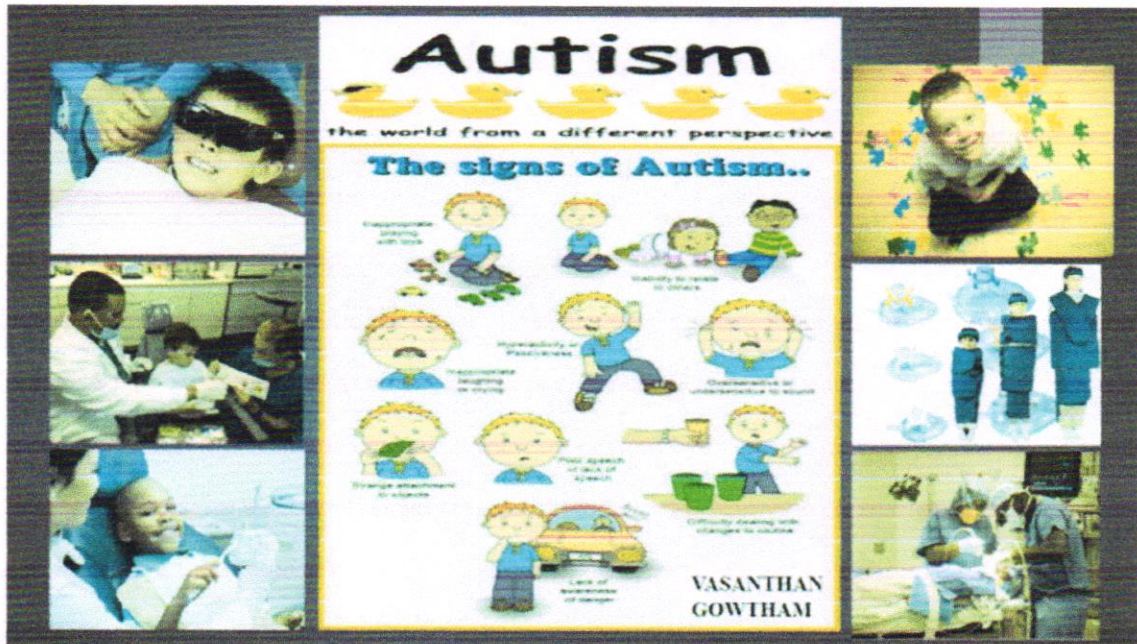
14. DO YOU KNOW THE PREVENTIVE MEASURES OF ORAL CANCER?

A) YES B)NO C)NOT SURE

15. ARE YOU AWARE OF THE TREATMENT MODALITIES OF ORAL CANCER?

A)YES B)NO C)NOT SURE

DEPARTMENT OF PEDODONTICS




Vasanthan

Principal
Sri Ramakrishna Dental College & Hospital
S.N.R. College Road, COIMBATORE - 641 006.

BIOPHOTONICS



- Phenothiazine Dyes
- Phthalocyanines
- Chlorines
- Porphyrins
- Xanthenes
- Monoterpenes




USHA NANDHINI
THENDRAL.M

PHYSICAL ABUSE



EMOTIONAL ABUSE



TATTOOING



MUNCHAUSEN SYNDROME BY PROXY



MOLLERA CAIDA



CHILD IN A THORNED CRADLE



SEXUAL ABUSE



SHAKEN BABY SYNDROME



VANMATHI
NIVEDHITHA

MANAGEMENT




DRY CUPPING



REMOVAL OF UVULA



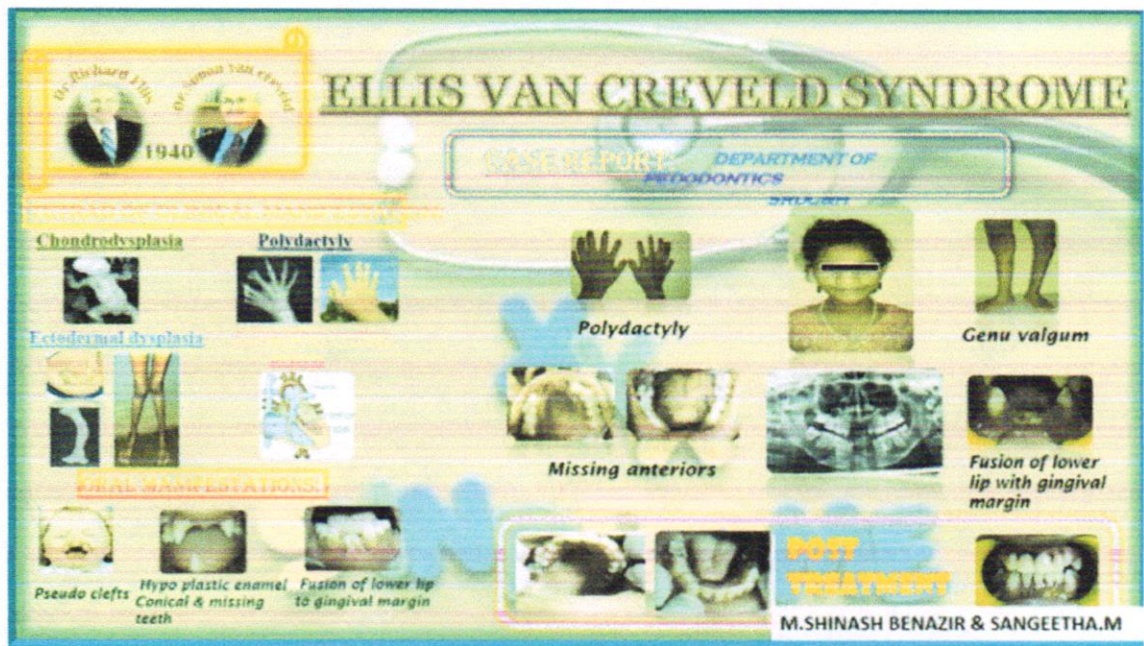
INTENTIONAL DRUGGING



DIAGNOSIS




Usha
Principal
Sri Ramakrishna Dental College & Hospital
S.N.R. College Road, COIMBATORE - 641 006.




ELLIS VAN CREVELD SYNDROME

CASE REPORT DEPARTMENT OF PEDODONTICS


Chondrodysplasia




Ectodermal dysplasia




Oral Manifestations



Pseudo clefts




Hypo plastic enamel
Conical & missing teeth




Fusion of lower lip
to gingival margin


Polydactyly




Polydactyly




Missing anteriors




Genu valgum



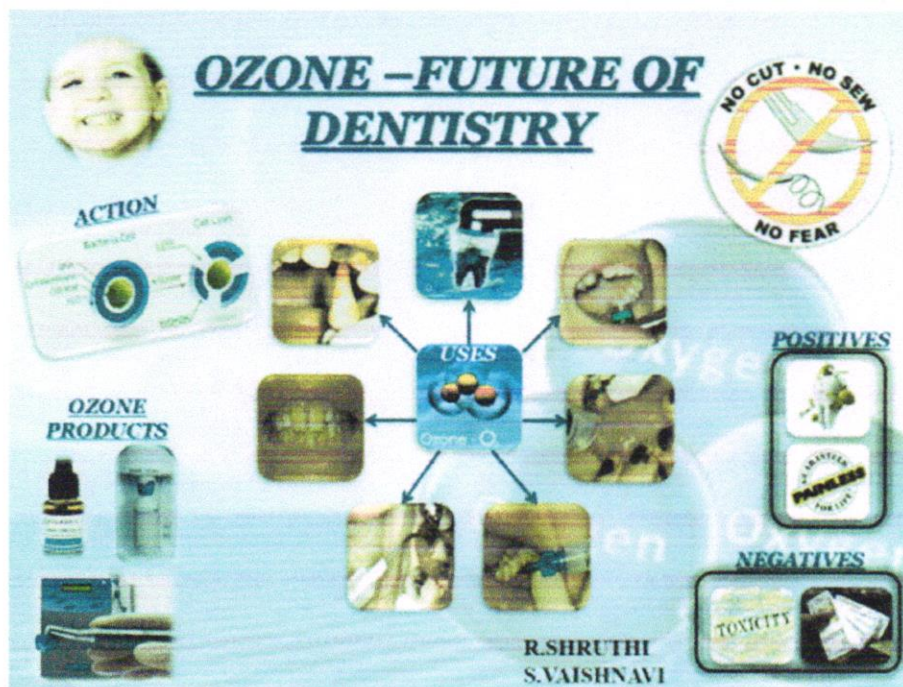
Fusion of lower lip with gingival margin



POT TREATMENT




M.SHINASH BENAZIR & SANGEETHA.M




OZONE - FUTURE OF DENTISTRY


ACTION



OZONE PRODUCTS




USES




**NO CUT • NO SEW
NO FEAR**

POSITIVES



NEGATIVES



R.SHRUTHI
S.VAISHNAVI

Principal
Sri Ramakrishna Dental College & Hospital
S.N.R. College Road, COIMBATORE - 641 006.

My Wednesday Is Indigo Blue!!

synesthesia

PAIN

EUPHEMISMS

Walla Walla Pediatric Dentistry

VALLIAMMAIL NIKITA.B

THE CANARY SYSTEM IN DENTISTRY

STILL WHY THE SAME ??

Canary numbers are generated to know the condition of the tooth

76

A low powered, laser based instrument with an intraoral camera

A low powered pulsating laser light is shown on the teeth during a 3 second scan

The pulses of laser light generate photo thermal and luminescence responses

Analyzes and measures the crystal structure

Measures upto a depth of 5 mm

Detects decay around orthodontic brackets

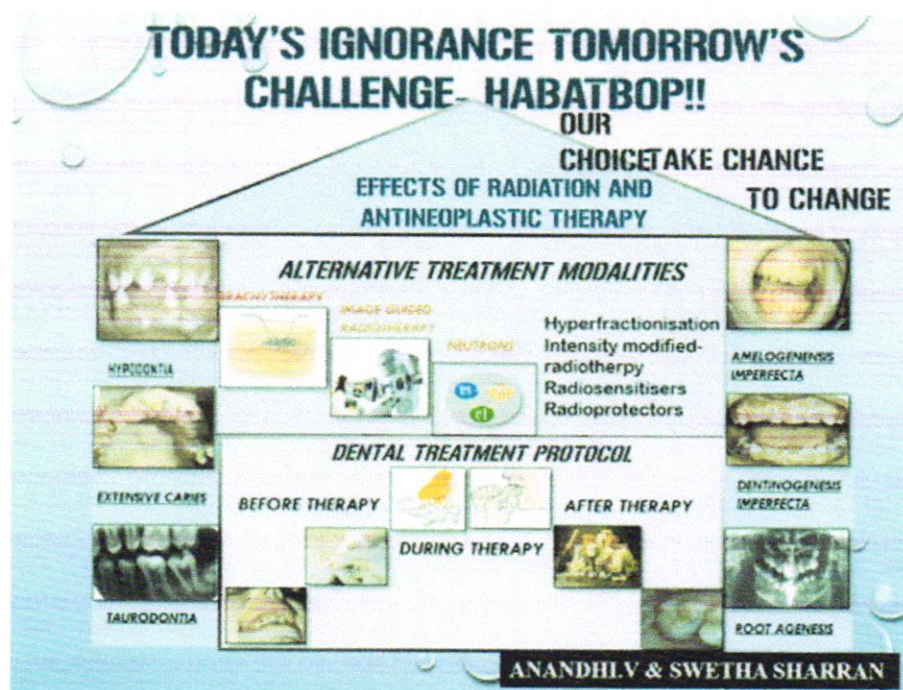
Under the restorations

Inter proximal regions and smooth surfaces

**N.SHANMUGA PRIYA
K.A.DHANUSHREE**

Handwritten signature

Principal
Sri Ramakrishna Dental College & Hospital
S.N.R. College Road, COIMBATORE - 641 006.



DEPARTMENT ACHIEVEMENTS: UNIVERSITY RANK UG/PG, BEST PAPER AWARDS

SL.NO	AWARDS BY STUDENTS
1	PRAKALYA- 9 TH UNDERGRADUATE PEDODONTICS CONVENTION, SREE BALAJI DENTAL COLLEGE AND HOSPITAL, CHENNAI ON 22 ND NOVEMBER 2019 - SECURED 3 RD PRIZE FOR TREATMENT OF ORAL MUCOCELE IN PAEDIATRICS USING DIODE LASER PAPER PRESENTATION
2	SHIWANI -9 TH UNDERGRADUATE PEDODONTICS CONVENTION, SREE BALAJI DENTAL COLLEGE AND HOSPITAL, CHENNAI ON 22 ND NOVEMBER 2019 - SECURED 3 RD PRIZE FOR TREATMENT OF ORAL MUCOCELE IN PAEDIATRICS USING DIODE LASER PAPER PRESENTATION
3	SOUNDARIYA G- 9 TH UNDERGRADUATE PEDODONTICS CONVENTION, SREE BALAJI DENTAL COLLEGE AND HOSPITAL, CHENNAI ON 22 ND NOVEMBER 2019- SECURED 2 ND PRIZE FOR BIOCHIPS PAPER PRESENTATION
4	SANJANA .J.M- 9 TH UNDERGRADUATE PEDODONTICS CONVENTION, SREE BALAJI DENTAL COLLEGE AND HOSPITAL, CHENNAI ON 22 ND NOVEMBER 2019 - SECURED 2 ND PRIZE FOR MAGNETIC NANO PARTICLES IN PULPECTOMY
5	SUNITHA .K- 9 TH UNDERGRADUATE PEDODONTICS CONVENTION, SREE BALAJI DENTAL COLLEGE AND HOSPITAL, CHENNAI ON 22 ND NOVEMBER 2019- SECURED 2 ND PRIZE FOR MAGNETIC NANO

[Handwritten Signature]

Principal
Sri Ramakrishna Dental College & Hospital
S.N.R. College Road, COIMBATORE - 641 006.

	PARTICLES IN PULPECTOMY
6	GOWTHAM .R- 9 TH UNDERGRADUATE PEDODONTICS CONVENTION, SREE BALAJI DENTAL COLLEGE AND HOSPITAL, CHENNAI ON 22 ND NOVEMBER 2019- SECURED 2 ND PRIZE IN INFILTRATION ICON PAPER PRESENTATION
7	SOUNDARYA RACHANA .R- 9 TH UNDERGRADUATE PEDODONTICS CONVENTION, SREE BALAJI DENTAL COLLEGE AND HOSPITAL, CHENNAI ON 22 ND NOVEMBER 2019- SECURED 2 ND PRIZE IN INFILTRATION ICON PAPER PRESENTATION
8	RAJSHREE .D- 9 TH UNDERGRADUATE PEDODONTICS CONVENTION, SREE BALAJI DENTAL COLLEGE AND HOSPITAL, CHENNAI ON 22 ND NOVEMBER 2019- SECURED 3 RD PRIZE FOR SILVER DIAMINE FLUORIDE PAPER PRESENTATION
9	VISHAL .S- 9 TH UNDERGRADUATE PEDODONTICS CONVENTION, SREE BALAJI DENTAL COLLEGE AND HOSPITAL, CHENNAI ON 22 ND NOVEMBER 2019- SECURED 3 RD PRIZE FOR SILVER DIAMINE FLUORIDE PAPER PRESENTATION
10	PRIYANKA .G- 9 TH UNDERGRADUATE PEDODONTICS CONVENTION, SREE BALAJI DENTAL COLLEGE AND HOSPITAL, CHENNAI ON 22 ND NOVEMBER 2019- SECURED 2 ND PRIZE IN PARENTAL ACCEPTANCE OF VARIOUS CHILD BEHAVIOUR MANAGEMENT TECHNIQUES
11	SAI NANTHINI .K- 9 TH UNDERGRADUATE PEDODONTICS CONVENTION, SREE BALAJI DENTAL COLLEGE AND HOSPITAL, CHENNAI ON 22 ND NOVEMBER 2019- SECURED 2 ND PRIZE IN PARENTAL ACCEPTANCE OF VARIOUS CHILD BEHAVIOUR MANAGEMENT TECHNIQUES
12	ROOBAVATHI M- 1 ST TAMILNADU IDA STATE STUDENTS' CONFERENCE, VINAYAKA MISSIONS SHANKARACHARIAR DENTAL COLLEGE ON 10,11 TH OF NOVEMBER 2018- AWARDED BEST PAPER
13	MADHUVANTHI GOPALAKRISHNAN- 1 ST TAMILNADU IDA STATE STUDENTS' CONFERENCE, VINAYAKA MISSIONS SHANKARACHARIAR DENTAL COLLEGE ON 10,11 TH OF NOVEMBER 2018- AWARDED BEST PAPER: AWARENESS ABOUT ORAL HEALTH STATUS OF 12-13 YR OLD SCHOOL GOING CHILDREN AMONG VARIOUS SOCIOECONOMIC GROUPS
14	ROOBAVATHI M- DENTAQUEST ,KARPAGAVINAYAGA INSTITUTE OF DENTAL SCIENCES ON 4 TH JANUARY 2018- SECURED 3 RD PRIZE FOR E POSTER PRESENTATION
15	NIKITHA B- 6 TH UNDERGRADUATE PEDODONTICS CONVENTION, SREE BALAJI DENTAL COLLEGE AND HOSPITAL, CHENNAI ON 25 TH NOVEMBER 2016- SECURED 1 ST PRIZE FOR SCIENTIFIC E-POSTER PRESENTATION
16	SRUTHI R -6 TH UNDERGRADUATE PEDODONTICS CONVENTION, SREE BALAJI DENTAL COLLEGE AND HOSPITAL, CHENNAI ON 25 TH NOVEMBER 2016- SECURED 1 ST PRIZE FOR SCIENTIFIC E-POSTER PRESENTATION
17	VALLIAMMAI L -6 TH UNDERGRADUATE PEDODONTICS CONVENTION, SREE BALAJI DENTAL COLLEGE AND HOSPITAL, CHENNAI ON 25 TH NOVEMBER 2016- SECURED 1 ST PRIZE FOR SCIENTIFIC E-POSTER



Principal

Sri Ramakrishna Dental College & Hospital
S.R.P. College Road, COIMBATORE - 641 006.

	PRESENTATION
18	VAISHNAVI S-6 TH UNDERGRADUATE PEDODONTICS CONVENTION, SREE BALAJI DENTAL COLLEGE AND HOSPITAL, CHENNAI ON 25 TH NOVEMBER 2016- SECURED 1 ST PRIZE FOR SCIENTIFIC E-POSTER PRESENTATION
19	SENAIKARASI RM- UG STUDENTS AND INTERN SCIENTIFIC MEET, MANIPAL COLLEGE OF DENTAL SCIENCES 23-24 APRIL 2015- SECURED 2 ND PLACE IN CLINICAL PAPER PRESENTATION



**SRI RAMAKRISHNA
DENTAL COLLEGE & HOSPITAL**

(Educational Service : SNR Sons Charitable Trust)

Affiliated to the Tamilnadu Dr. M.G.R. Medical University, Chennai.
Recognised by Dental Council of India, New Delhi



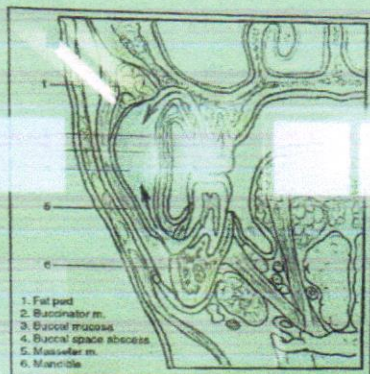
DEPARTMENT OF CONSERVATIVE DENTISTRY AND ENDODONTICS

S.NO	PROJECT	NAME OF THE STUDENTS
1	CANAL CONFIGURATION (3 NOS)	DR.REMYA VARGHES,E DR.KEERTHANA, DR.DEVINA
2	KRASNER AND RANKOW'S LAWS(4 NOS)	DR.SAKTHIVEL, DR.VARSHINI. DR.SHALINI
3	MANDIBULAR SPACE INFECTIONS	DR.ANAGHA
4	CANINE SPACE INFECTION	DR.MOHAMED NOORUL HASAN
5	BUCCAL SPACE INFECTION	DR.PON MATHINI
6	NSAIDS IN DENTISTRY	DR.JAYASHREE ROJA
7	ANTIBIOTICS IN DENTAL INFECTIONS	DR. MOHAMED ASHIF ANIFA
8	DRUGS IN CARDIAC PATIENTS	DR. REVATHI. P

Principal
Sri Ramakrishna Dental College & Hospital
S.N.R. College Road, COIMBATORE - 641 006.

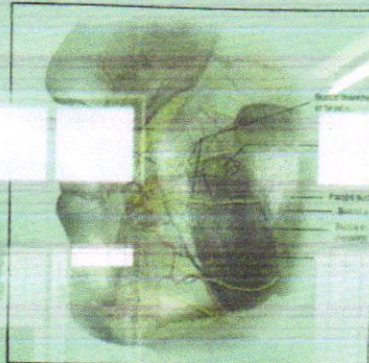
BUCCAL SPACE INFECTION

ANATOMY & BORDERS



CONTENTS

Buccal pad fat, Stensons duct and Facial artery

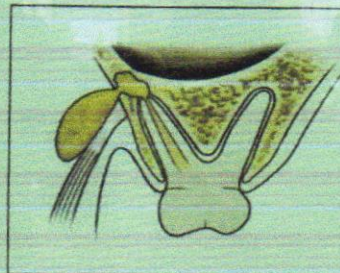


ROUTE OF INFECTION

Infected maxillary and mandibular posterior teeth

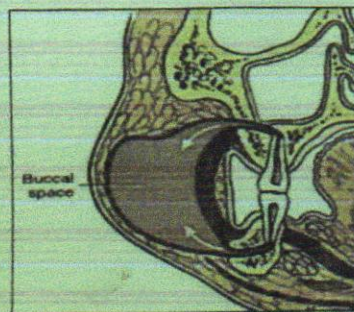
CLINICAL MANIFESTATIONS

- ❖ Extra oral swelling below zygomatic arch and above inferior border of mandible and anterior to masseter muscle



MANAGEMENT

- ❖ I & D (Extra orally - Below the lower border of the mandible and Intra orally - buccal vestibule)
- ❖ Management of offending teeth
- ❖ Appropriate antibiotic therapy



BY DR PON MATHINI
2nd yr PG TRAINEE

[Signature]

Principal

Sri Ramakrishna Dental College & Hospital
S.N.R. College Road, COIMBATORE - 641 006.

* Salivary Glands The floor of the pulp chamber is always located in the centre of the tooth at the level of (3).

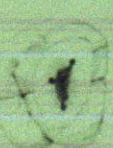



Radius of curvature: The walls of the pulp chamber are the convex at the level of CEJ, that is, the external root surface is concave.

Location of the canals: The inlets of the roof canals are always located at the junction of the walls and the floor.

NOTE ON FIGURE 2: The apices of the root canals are located at the angles with a floor-wall junction.

Law of Active Migration 2. The surfaces of the root cells are located at the terminals of the root.



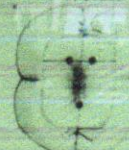
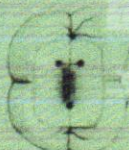
Law of colour change: The colour of the pulp chamber floor is always darker than the walls.



Law of Cos: The distance from the center of the circle to the center of the circle is the same through all the circles. The distance from the center of the circle to the center of the circle is the same through all the circles. The distance from the center of the circle to the center of the circle is the same through all the circles.

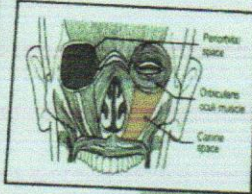
Methodology: Except for the material, which the authors of the *Journal of Management Inquiry* have drawn in a mental data direction, through the pulp, a random flow.

Let α be the distance from the center of the circle to the center of the floor of the sub-chamber. The distance from the center of the circle to the center of the floor of the sub-chamber is α .

[illegible]


Principal
Sri Ramakrishna Dental College & Hospital
S.N.R. College Road, COIMBATORE - 641 006.

CANINE SPACE



The boundaries:

- Anterior: the nasal cartilages
- Posterior: the buccal space
- Superior: the quadratus labii superioris muscle (levator labii superioris)
- Inferior: the oral mucosa of the maxillary labial sulcus
- Superficial: the quadratus labii superioris muscle
- Deep border: the levator anguli oris muscle

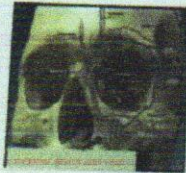

Etiology:

- Deep seated infections in relation to Maxillary canine or maxillary first premolar.
- Rarely from nasal & upper lip infections.
- Odontogenic infections may spread to involve the canine space.

Clinical Significance:

- Swelling lateral to the nose over cheek.
- Obliteration of the nasolabial fold.
- Swelling of the upper lip.
- Oedema occurs in lower eyelid leading to closure of eye.



The contents:


- The angular artery and angular vein
- The infra-orbital nerve (a branch of the maxillary division of the trigeminal nerve)



Treatment:

- Antibiotic prophylaxis
- Incision is made intraorally high in the maxillary labial vestibule.
- Small hemostat is inserted through levator anguli oris into abscess cavity.
- Drainage with drain secured

R. Mohamed Nourul Hasan
Post Graduate Trainee


Principal
Sri Ramakrishna Dental College & Hospital
S.N.R. College Road, COIMBATORE - 641 006.

DRUGS IN CARDIAC PATIENTS			
INFECTIVE ENDOCARDITIS PROPHYLAXIS - SINGLE DOSE REGIMEN (30-60 MINUTES PRIOR TO THE PROCEDURE) (AHA / ACC 2017)			
SITUATION	AGENT	ADULTS	CHILDREN
Oral	Amoxicillin	2 g Oral	50mg/kg, Oral
Unable to take oral route	Ampicillin	2g IM/IV	50mg/kg, IM/IV
	Cefazolin/Ceftriaxone	1g IM/IV	50mg/kg, IM/IV
Allergic to Penicillin / Ampicillin	Cephalexin	2g Oral	50mg/kg, Oral
	Clindamycin	600mg Oral	20mg/kg, Oral
	Azithromycin/Clarithromycin	500mg Oral	15mg/kg, Oral
Allergic to Penicillin / Ampicillin & Unable to take oral route	Cefazolin/Ceftriaxone	1g IM/IV	50mg/kg, IM/IV
	Clindamycin	600mg IM/IV	20mg/kg, IM/IV
LOCAL ANESTHETICS	Safe dose of Adrenaline in a cardiac patients : 0.04 mg. We can administer up to 2 cartridges containing 1:1,00,000 Epinephrine.		
NSAIDS	Selective COX-2 inhibitors are unsafe. Patients taking non selective β blockers should avoid prolonged use of NSAIDS. Paracetamol & Naproxen can be given with caution.		

PG DEPT OF CONSERVATIVE DENTISTRY AND ENDODONTICS

DR. REVATHI, P

ANTIBIOTICS IN DENTAL INFECTIONS			
AMOXICILLIN Active against gram positive and gram negative facultative anaerobic bacteria Amoxil Novamox Dose: 500 mg/6 hrs, 1000 mg/12 hrs Side effect: Diarrhea, nausea, hypersensitivity		AMOXICILLIN-CLAVULANIC ACID Additional activity against beta lactamase producing bacteria Moxclav Moxclav Dose: 500 mg/6 hrs, 1000 mg/12 hrs Side effect: Diarrhea, nausea, hypersensitivity	
FENICILLIN Useful in infection caused by streptococcus and staphylococcus Koypen Dose: 500mg/6 hrs Side effect: Nausea, vomiting, diarrhea, abdominal pain, hypersensitivity		CLINDAMYCIN Useful in penicillin allergic patients Active against streptococcus, staphylococcus, gram positive bacteria Clavexin Aviclin Dose: 300 mg/6 hrs Side effect: Nausea, diarrhea, pseudotumor cerebri	
METRONIDAZOLE Active against obligate anaerobes Metrogyl Flagyl Dose: 500-750mg/6 hrs Side effect: Sore throat, metallic taste, discolored urine, incompable with alcohol ingestion		ERYTHROMYCIN Active against gram positive and gram negative bacteria. Effective against both the facultative and obligate anaerobe. Useful in penicillin allergic patients Erythrocin Erycin Dose: 250-500mg/6 hrs Side effect: GI intolerance, hepatotoxicity, nausea	

Dr. Mohamed Ashif Anis
PG Dept Of Conservative Dentistry And Endodontics

Principal
Sri Ramakrishna Dental College & Hospital
S.N.R. College Road, COIMBATORE - 641 011

NSAIDS IN DENTISTRY

Commonly used



Ibuprofen

Adult dose: 400-600mg/6-8 h

Pediatric dose:

20 mg/kg/day in 3-4 doses

Third trimester of pregnancy
Lactation
Asthmatic patients

Acetofenac

Adult dose: 100 mg once or twice a day

Pediatric dose: NOT recommended



Peptic ulcer
Hepatic impairment
Ischemic Heart Disease
Third trimester of pregnancy

Paracetamol:

Adult dose: 325-650 mg/4-6 h

1 q/8 h

Pediatric dose: 10 mg/kg every 4 h

15 mg/kg every 6 h



Hepatic impairment
Chronic alcoholic patients

Adult dose: 20 mg in starting dose + 10 mg/4-6 h

Post operatively

Pediatric dose:

NOT recommended under age 16 years



Asthma
Peptic ulcer
Hepatic impairment



SHARED TOXICITIES

Cardiovascular risk

GI side effects

Miscarriage

Bleeding

Allergy

JAYA SHREE ROJA R
PG Dept Of Conservative
Dentistry and Endodontics



[Signature]

Principal

Sri Ramakrishna Dental College & Hospital
S.N.R. College Road, COIMBATORE - 641 006.

MANDIBULAR SPACE INFECTIONS

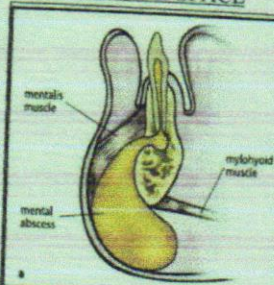
Boundaries-

- Roof: mylohyoid muscle.
- Inferior: deep cervical fascia, platysma, superficial fascia & skin.
- Laterally: anterior belly of digastric.
- Posteriorly: submandibular space.

Etiology-

- Infected mandibular incisors.
- Anterior extension of submandibular space.

SUBMENTAL SPACE



Clinical Features-

- Chin appears glossy & swollen.
- Pain & discomfort on swallowing

Treatment-

- I and D at the most inferior aspect of swelling in submental region bilaterally.
- RCT of the tooth/Extraction of hopeless tooth
- Supportive antibiotics

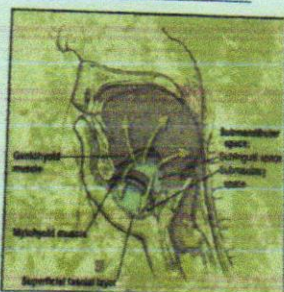
Boundaries-

- Superiorly: mucosa of floor of mouth.
- Inferior: mylohyoid muscle.
- Posteriorly: body of hyoid bone.
- Anteriorly & laterally: inner aspect of mandibular body.
- Medially: geniohyoid, styloglossus, genioglossus muscle.

Etiology-

- Infected mandibular premolar & 1st molar.

SUBLINGUAL SPACE



Clinical Features-

- Swelling of floor of mouth.
- Elevated tongue.
- Pain & discomfort on swallowing.

Treatment

- I and D intra orally at the base of the alveolar process in the lingual sulcus.
- Root Canal Treatment of the tooth / Extraction of hopeless tooth
- Supportive antibiotics

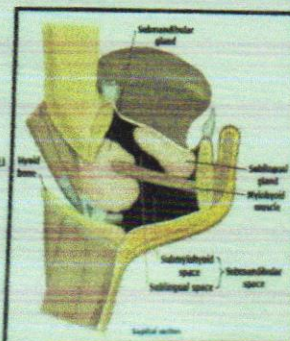
Boundaries-

- Superiorly: mylohyoid muscle, inferior border of mandible.
- Inferior: anterior & posterior belly of digastric.
- Laterally: deep cervical fascia, platysma, superficial fascia & skin.
- Medially: hyoglossus, styloglossus, mylohyoid muscle.
- Posteriorly: to hyoid bone.
- Anteriorly: submental space.

Etiology-

- Infected mandibular 2nd & 3rd molars.
- From submental, sublingual spaces.

SUBMANDIBULAR SPACE



Clinical Features-

- Indurated swelling in sub mandibular region.

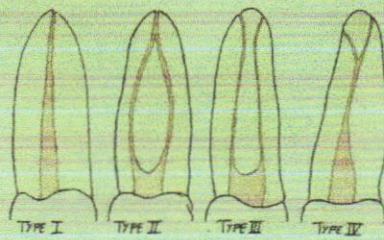
Treatment

- Incision and drainage at the inferior aspect of the swelling in the shadow of the mandible
- RCT of the tooth or extraction of hopeless tooth
- Supportive antibiotics

ANAGHA C.S.
2nd YR PG TRAINEE

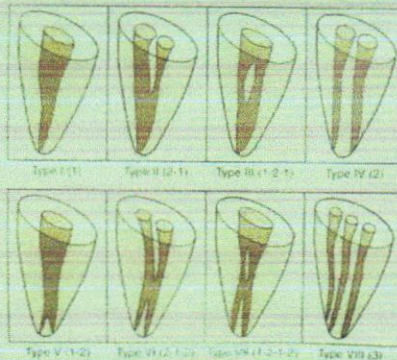

Principal
Sri Ramakrishna Dental College & Hospital
S.N.R. College Road, COIMBATORE - 641 006.

CANAL CONFIGURATIONS - BY WEINE

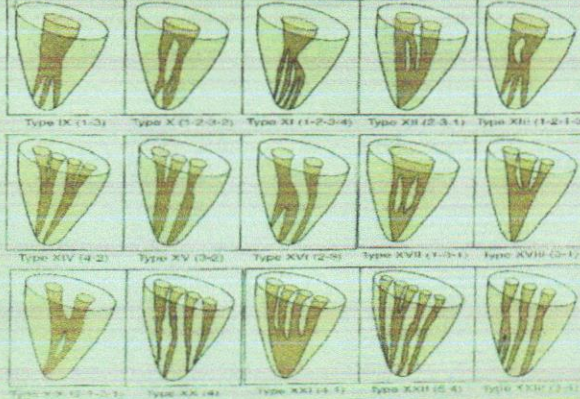


TYPE I: Single Canal Near Root Apex
TYPE II: Two Canals Arising from Root Apex
TYPE III: Two Canals Arising from Root Apex, One Curved
TYPE IV: One Canal Arising from Root Apex, One Curved

VERTUCCI'S CLASSIFICATION

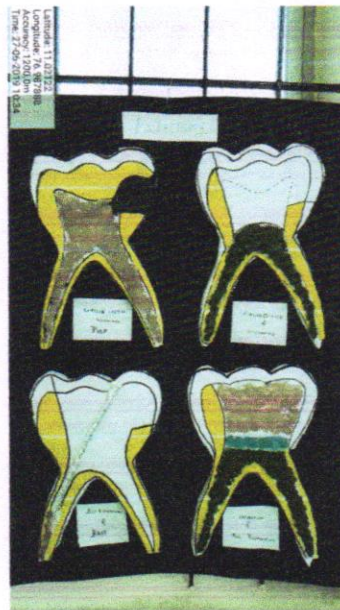
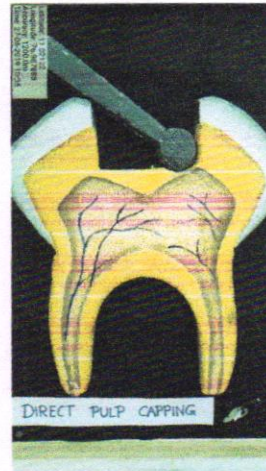
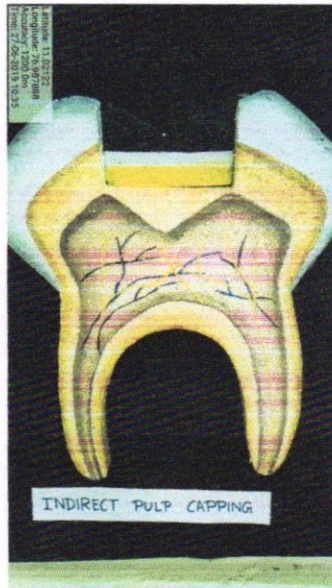



SERT AND BAYIRLI'S ADDITIONAL CANAL TYPES TO VERTUCCI'S CLASSIFICATION

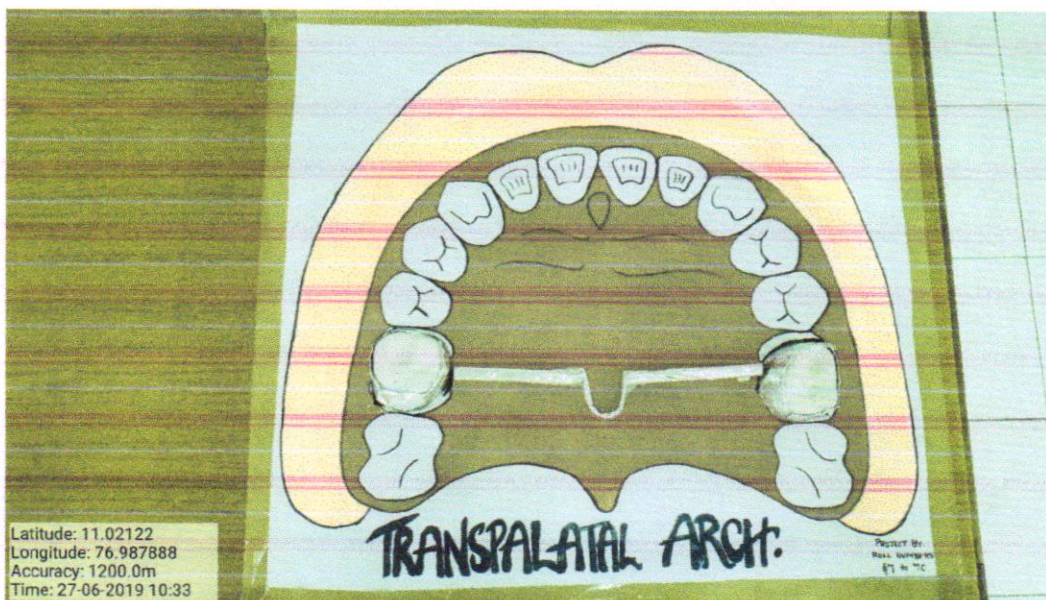


[Signature]
Principal
Sri Ramakrishna Dental College & Hospital
S.N.R. College Road, COIMBATORE - 641 006.

DEPARTMENT OF PEDODONTICS - STUDENT PROJECTS




Principal
Sri Ramakrishna Dental College & Hospital
S.N.R. College Road, COIMBATORE - 641 006,



[Signature]

Principal
Sri Ramakrishna Dental College & Hospital
S.N.R. College Road, COIMBATORE - 641 006,

NANCE PALATAL ARCH APPLIANCE

INTRODUCTION :-

- BILATERAL
- FIXED
- PASSIVE
- BANNED
- NON-FUNCTIONAL SINCE PAINFUL

DESIGN :-

THE ARCHED WIRE EXTENDS FROM THE PALATAL SURFACE OF ONE MOLAR BAND TO THE OTHER. ANTERIORLY, IT EXTENDS UP TO THE RUAAE AREA AND IS EMBEDDED IN AN ACRYLIC BUTTON WHICH IS FIRMLY PLACED ON THE RUAAE PROVIDES GOOD ANTIROTATION.

INDICATIONS :-

CONTRAINDICATIONS :-


- MOLAR ROTATION
- MOLAR STABILIZATION AND ANCHORAGE
- MOLAR DISTALIZATION IN BILATERAL MISSING OF DECIDUOUS MOLAR IN UPPER ARCH
- CLASS II MALOCCLUSION IN WHICH PREMOLARS ARE REMOVED
- CLASS II MALOCCLUSION - NON SURGICAL CASES

MODIFICATION :-

- WITH ANTERIORLY PLACED ACRYLIC BUTTON PROVIDE A FIXED ACRYLIC "LAME ANTERIOR GUE TONE IN ANTERIOR DEEP BITE"
- ANTEROPOSTERIOR PACKING IN CASE OF CANINE RETRACTION
- OTHER NANCE BUTTON TO ANTEROPOSTERIOR PLACED LATERAL INCISORS


DISADVANTAGES :-

- ACRYLIC BUTTON MAY IRRITATE THE SOFT TISSUES
- ORAL HYGIENE DIFFICULTIES



Latitude: 11.02122
Longitude: 76.987888
Accuracy: 1200.0m
Time: 27-06-2019 10:31




Principal
Sri Ramakrishna Dental College & Hospital
 S.N.R. College Road, COIMBATORE - 641 006.